

Eastern Roman Mounted Archers and Extraordinary Medico-Surgical Interventions at Paliokastro in Thasos Island during the ProtoByzantine Period

**The Historical and Medical History Records
and the Archaeo-Anthropological Evidence**

Anagnostis P. Agelarakis

Access Archaeology





ARCHAEOPRESS PUBLISHING LTD
Summertown Pavilion
18-24 Middle Way
Summertown
Oxford OX2 7LG
www.archaeopress.com

ISBN 978-1-78969-601-1
ISBN 978-1-78969-602-8 (e-Pdf)

© Anagnostis P. Agelarakis and Archaeopress 2020

Cover: © Argie Agelarakis - 'Spirits of Ancient Cavalry Warriors on the Battlefield'

All rights reserved. No part of this book may be reproduced, stored in retrieval system, or transmitted, in any form or by any means, electronic, mechanical, photocopying or otherwise, without the prior written permission of the copyright owners.

This book is available direct from Archaeopress or from our website www.archaeopress.com

Contents

Introduction.....	1
The archaeological site, finds, relative dating, project overview	3
The anthropological record and aspects of burial practices	8
Taphonomy and Skeletal Preservation	11
Analysis of Anthropological Material.....	11
Dental Anthropology	11
Reconstructions of <i>ante mortem</i> kinetics indicative of habitual/occupational tasks	12
Palaeopathology of trauma cases and the footprint of an experienced physician-surgeon	13
Precedents in early Greek, and Roman medical history for the treatment on limb fractures	17
Palaeopathological assessments of infectious complications.....	23
About the physician-surgeon, the <i>Ιητρείον</i> , and the context of Paliokastro.....	24
Paliokastro (the old fort) and the aim for the prosopography of its female and male riders	27
Mounted archers of Paliokastro	28
Historical references on the Roman army and the ProtoByzantine mounted archer/lancer	28
Reflections on archery, and the type and capacity of bows and arrows used by the Roman mounted archer in battle versus these of the ‘barbarian’ enemies	30
Historical references on Roman enemies and their invasions in the region of Thasos: Antae, Avars, Bulgars, Huns, Sclaveni, Kutrigurs.....	32
Historical references on barbarian raids and their consequences in Thrace and Macedonia	33
Towards a chronology of events for the harassment of Thasos by enemy incursions	36
Archaeological evidence of catastrophic events in Thasos during the ProtoByzantine period	37
Aiming towards concluding remarks on the ProtoByzantine ‘Paliokastrétes’	38
The case study of the <i>Wounded Caballarius</i> ’ head/neck pathology, the ways of the cranial surgery and trephination, and few palaeopathological reflections.....	40
Acknowledgements	50

List of Figures and Tables

Figure 1. Thasos island in a regional map of the Eastern Roman Empire, rendering by Argie Agelarakis	1
Figure 2. Map of Thasos island, with the location of its capital city Limenas, its villages and settlements, and the location of Paliokastro (see arrow) in the region of Rachoni village, rendering by Argie Agelarakis	2
Figure 3. Seaward view of Rachoni region and location of Paliokastro site	3
Figure 4. Field of view just above the olive groves of Rachoni village, at a lower elevation than the site of Paliokastro	4
Figure 5. Uncovering the slab stones from the graves within the <i>naiskos</i> ' floor	5
Figure 6. The four graves within the <i>naiskos</i> ' floor	5
Figure 7. North, long, wall of grave No. 2.	6
Figure 8. <i>Pessokranon</i> , decorative architectural component of <i>naiskos</i>	6
Figure 9. Thasos archaeological Museum laboratory; Adelphi student assistants during the skeletal analysis.....	9
Table 1. Basic archaeological proveniences and demographic profile of Paliokastro population sample.....	9
Figure 10. Anthropological remains <i>in situ</i>	10
Figure 11. Sample case on dental anthropology	11
Figure 12. Colles fracture healed, palaeopathological manifestations, and matters of skeletal preservation	15
Figure 13. Anterior view of bilateral tibial diaphyseal healed fractures.....	17
Figure 14. Length of tibial callus on its anterior crest	17
Figure 15. X-ray imaging of bilateral healed tibial fractures with corresponding <i>loci</i> of the skeletal samples.....	18
Figure 16. X-ray imaging of bilateral healed tibial fractures focusing on the right tibial callus formation.....	18
Figure 17. Degrees of bilateral tibial diaphyseal posterior angulation on the sagittal plane.....	22
Figure 18. Active, in the healing process, and healed periosteal tibial diaphyseal reactions	23
Figure 19. Fibular diaphysis showing manifestations of infectious complications.....	24
Figure 20. Bilateral fibular diaphyseal infectious complications, with healed fracture <i>locus</i> (red arrows)	25
Figure 21. Map of the northern Aegean shores and mainland regional to Thasos island [Excerpt from Weigel, C., (1720), <i>Descriptio Orbis Antiquae</i> , XLIV <i>Tabulis, Graeciae Septentrionalis Pars</i> , Nuremberg]: (1) Thasos island, (2) <i>Ulpia Topirus</i> (Topirus), (3) Anastasioupolis (<i>Stabulo Diomedis</i> at its earlier Roman phase, and Peritheorion in the Late Byzantine Period), (4) Neapolis (later Christopolis, and subsequently Kavala), and (5) Philippi	35

Figure 22. Ectocranial left latero-posterior view of cranial component showing surgical intervention..... 41

Figure 23. Ectocranial view of palaeopathological specimen: a) red arrow points to orifice on the mastoid process, and b) surgical preparation dimensions peripheral to trephination..... 42

Figure 24. Cranial palaeopathological specimen with dimensions of two ectocranial *loci* showing surgical interventions..... 43

Figure 25. Cranial palaeopathological specimen showing surgical interventions, with dimensions of trephined *locus*..... 43

Figure 26. X-ray imaging of cranial palaeopathological specimen with samples of relevant identifiers.... 46

Figure 27. Close up endocranial view of cranial palaeopathological specimen..... 47

Figure 28. Right frontal bone fragment showing palaeopathological changes within the orbital roof 47

Eastern Roman Mounted Archers and Extraordinary Medico-Surgical Interventions at Paliokastro in Thasos Island during the ProtoByzantine Period: The Historical and Medical History Records and the Archaeo-Anthropological Evidence

Introduction

Sailing through the waters of her western passage, your gaze is lost in the beauty so generously bestowed upon Thasos Island (Figures 1, and 2). Girded by Poseidon's deep blue sea its littoral emerald-like garlands and gilded beaches graciously yield to Athena's greyish-green ornaments, swaying delicately to the touch of the mistral, dressing up the uplands towards the imposing foothills of Mount Ipsarion. At the very first instance you lay eyes upon her, she entices you to discover her...perhaps just as she

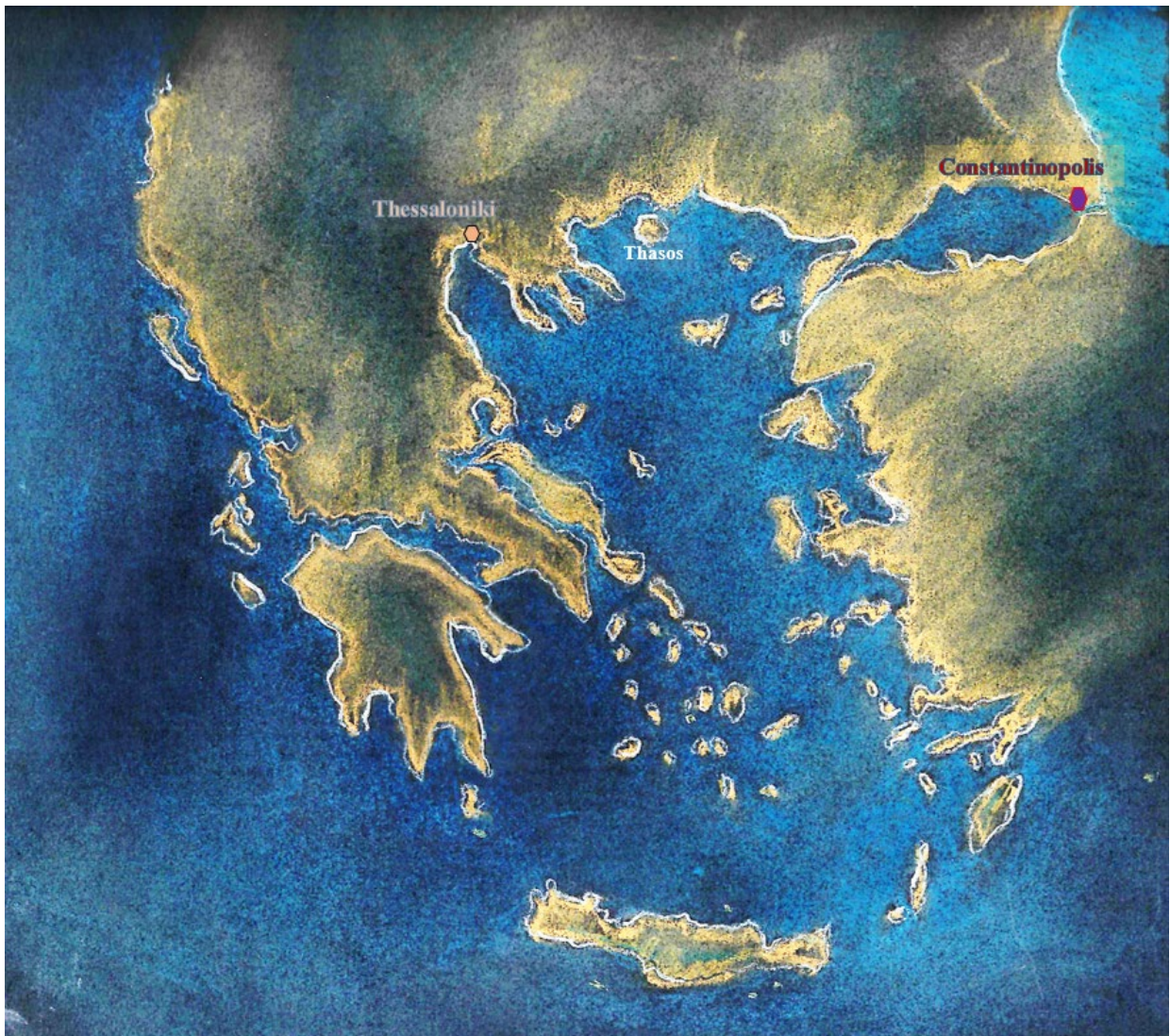


Figure 1. Thasos island in a regional map of the Eastern Roman Empire, rendering by Argie Agelarakis.

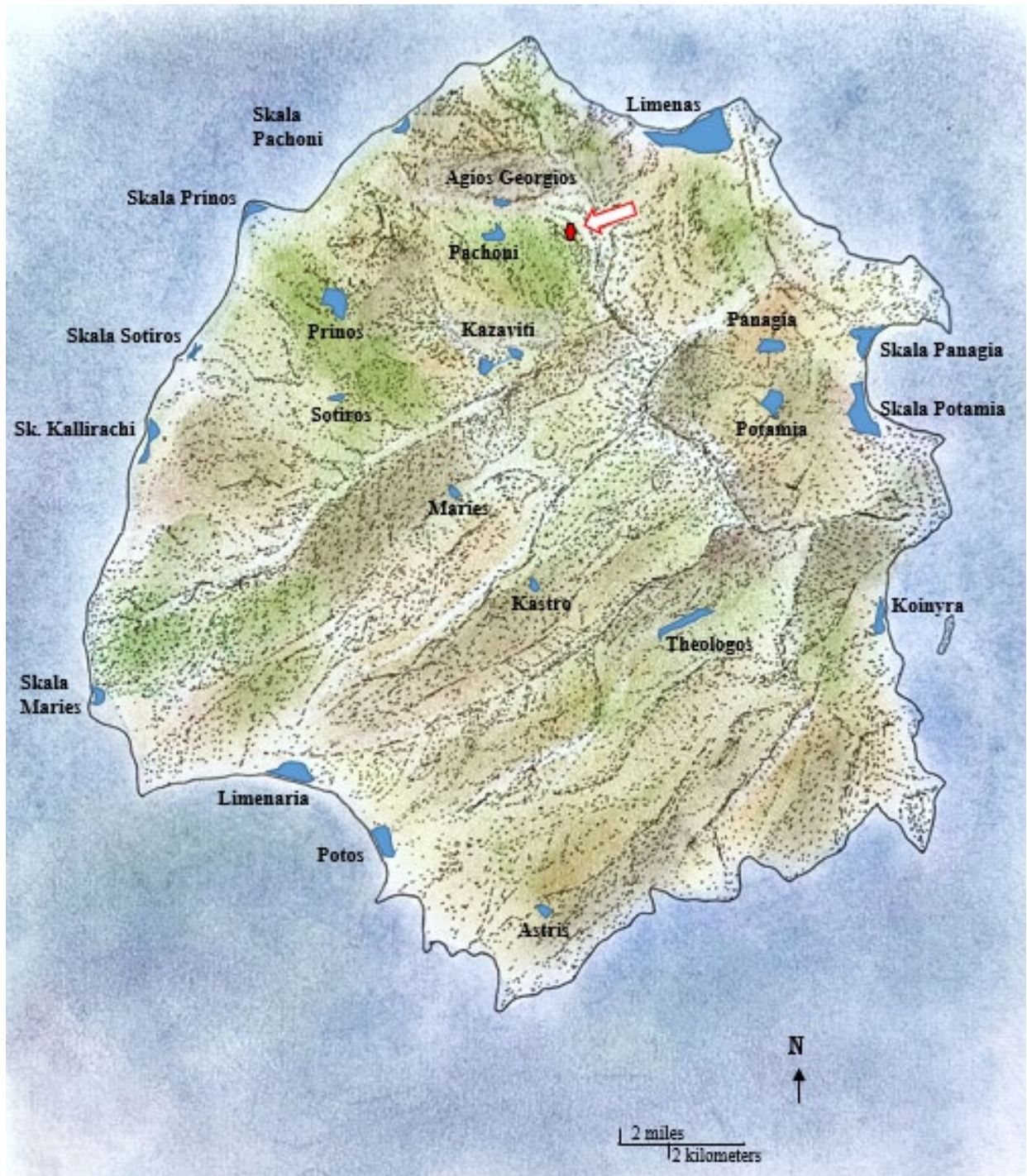

Figure 2. Map of Thasos island, with the location of its capital city Limenas, its villages and settlements, and the location of Paliokastro (see arrow) in the region of Rachoni village, rendering by Argie Agelarakis.

did back then, with Parian Tellis and Kleobeia.¹ Moreover, in the midst of the wealth of this enchanting beauty, you may at first unwittingly overlook the spread of vestiges of diachronic human dynamics

¹ Agelarakis, A. P., (2017), *Parian Polyandria: The Late Geometric Funerary Legacy of Cremated Soldiers' Bones on Socio-Political Affairs and Military Organizational Preparedness in Ancient Greece*, Archaeopress, Oxford; Agelarakis, A. P., and Zafeiropoulou, F., (2017), 'Parian Polyandria and the Military Legacy of Archilochus' Forebears', in (Ed.) D. Mulliez, *Métropole et colonies, Proceedings of International Symposium-Memorial Marina Sgourou*, Recherches Franco-Hellénique, École




Figure 3. Seaward view of Rachoni region and location of Paliokastro site.

nestled between steep rocky hills and the mantles of her green valleys. But when kneeling respectfully to search and attentively study the plethora of cultural elements and achievements of the rich history of the Thasians, guarded with lavish care over the passage of time by the earth of Thasos, the island's rare beauty becomes enriched with unprecedented as often complex bearings unveiled from the folds of Cleo's parchments.

The archaeological site, finds, relative dating, project overview

On one of the island's exquisite mountain slopes (Figure 3), densely crowned with oak, spruce and chestnut trees, trellised by labyrinthine age old ivies and impenetrably thick bushes, concealed high up above the olive groves of Rachoni village, the steep and remote site known as Paliokastro (translated as 'old fort'), at a 460 meter elevation, strategically commands with an eagle-eyed view the plain below, overseeing straight over the expanse of the Aegean sea across, towards Paggaion mountain imposing on the mainland (Figure 4) of Eastern Macedonia. There, at Paliokastro, an archaeological rescue excavation carried out in 2000, under the supervision of archaeologist Dr. Efstratios (Stratis) Papadopoulos, brought to light an orderly cluster of four adjacent and uniformly structured graves, clustered at the western end in the floor of a notable quadrangular building² with exterior dimensions of 10.0 m (E-W) by 5.0 m (N-S), wall thickness of 0.70 m, and a surviving maximum wall height at the time of excavation³ of 1.10

Française d' Athènes, Paris, pp. 47–6; Zafeiropoulou, F. and Agelarakis, A. P., (2005), 'Warriors of Paros', *Archaeology*, 58.1, pp. 30–35.

² The shared long walls between the box-shaped/quadrangular graves, positioned on an E-W orientation as that of the building itself, measured a thickness from 30.0 to 32.0 cm; the internal dimensions of the graves measured 2.07 m. in length by 0.72 m in width, and ca. 1.0 m in depth. While only one of the graves, grave No. 1, had been coated internally by a layer of plaster, each of the four graves was covered by four gneiss slab stones, of the same type, craftsmanship, and relevant thickness dimensions (mostly of 0.12 m) as those of the rest of the building floor.

³ Excavation recordings are courtesy of Dr. S. Papadopoulos, currently Ephor of Prehistoric and Classical Antiquities of Drama prefecture. Additional excavation data were gathered through numerous communications with Dr. Papadopoulos over the years since 2002 (start of the osteological analysis of site materials at the Archaeological Museum of Thasos) until the drafting of the present work.